



## PATIENT INFORMATION SHEET

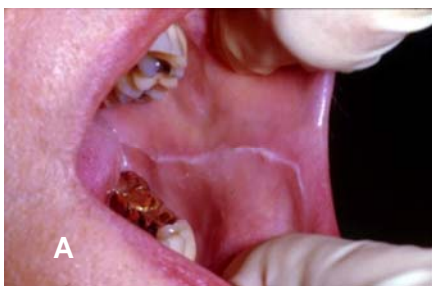# Premalignant Oral Lesions

A routine part of an oral examination should be inspection not only of the teeth and gums but also of the soft tissues in and around the mouth. Dentists look for abnormal changes that are loosely called “lesions.” Many lesions are innocuous and can be easily diagnosed and named based upon their appearance alone. However, some lesions are not as easy to identify and require additional diagnostic steps, such as a biopsy (removal of a piece of the lesion to examine under a microscope). A small percentage of these lesions may be premalignant or even malignant (see education sheet on Oral & Oropharyngeal Cancer).

**What are these?** Premalignant or precancerous (also referred to as “potentially malignant”) oral lesions involve the skin lining of the mouth (known as the epithelium) and may be at risk for becoming (transforming into) an oral cancer, although it is difficult to predict which lesions will transform and how long it will take (see below).

**Who is at risk for these?** As we grow older our risk of developing cancer increases. The same is true for premalignant lesions. Most lesions are detected in people over the age of 40 and those with similar risk factors for oral cancer, such as tobacco and/or heavy alcohol use, although such lesions can also be found in younger individuals and/or those without classic risk factors.

**How are oral lesions detected?** Premalignant lesions and early cancers are usually asymptomatic (ie the patient has no pain and they don’t even know they have a lesion), so their detection is contingent upon a careful soft tissue examination by a dentist. This examination must include the inside and outside of the lips, the cheeks (buccal mucosa), the sides and undersurface of the tongue, the floor of mouth, the gums, the roof of the mouth (palate), the back of the mouth/top of the throat (oropharynx). Most oral lesions are traumatic in nature and have no potential for cancer (Figure A). However, some oral lesions have an appearance which may raise suspicion by the dentist.



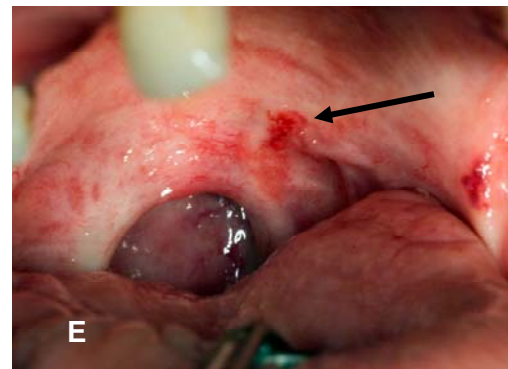
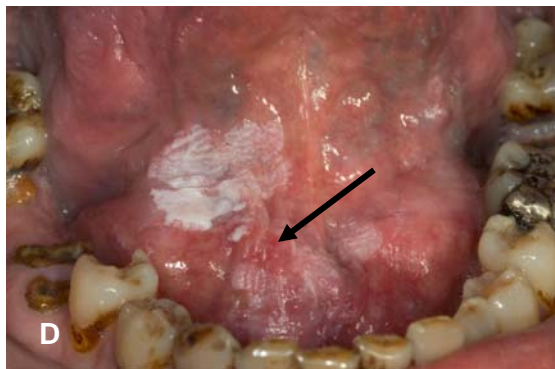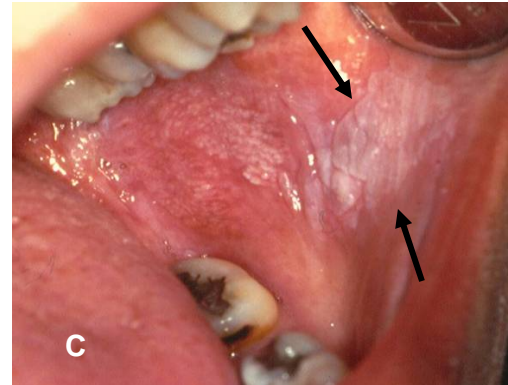
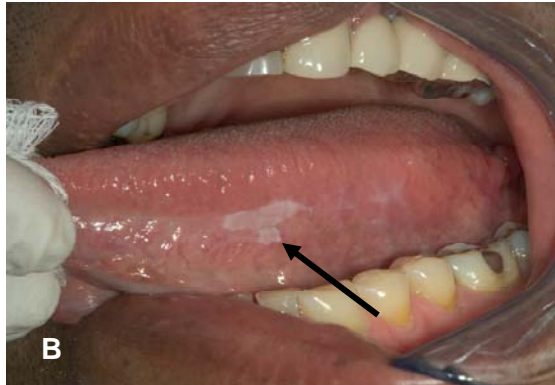**Figure A:** The whitish line is a common lesion that develops as a reaction to pressure of the soft tissue against the teeth. This readily identifiable lesion is termed linea alba (white line) and has no potential for cancer.

**Which lesions might raise suspicion?** Patches that are, red, white or mixed red/white in color, or that may also be ulcerated (ie an area where the lining epithelium is lost), especially when found on “high-risk” sites such as the side (lateral surface), underside of the tongue (ventral surface), floor of mouth, or at the back of mouth/top of the throat (oropharynx). A white patch that cannot be wiped off with gauze and for which an explanation is not obvious to the dentist may be defined as a leukoplakia (Figure B & C next page). Similarly, reddish patches with no obvious cause can be defined as erythroplakia (Figure D next page) and mixed red and white areas termed erythroleukoplakia (Figure E next page). Lesions with a red component carry the highest potential for being premalignant or becoming malignant. Some dentists use additional technologies to look for or characterize suspicious lesions (known as diagnostic adjuncts). It is essential to establish an accurate diagnosis for all such lesions that raise suspicion.



## PATIENT INFORMATION SHEET

# Premalignant Oral Lesions



**Figure B:** Leukoplakia on the left lateral tongue in a non-smoker. The biopsy showed premalignant changes (dysplasia). At 5 years of follow-up this area has not transformed to cancer.

**Figure C:** Leukoplakia of the cheek (buccal mucosa) in a smoker. The biopsy showed dysplasia and within 3 years this area became cancerous (squamous cell carcinoma).

**Figure D:** Erythroleukoplakia - red (arrow) and white areas in the floor of the mouth of a smoker that showed premalignant changes (dysplasia)

**Figure E:** Erythroplakia- (arrow) on the soft palate. A biopsy revealed dysplasia

**How is the diagnosis made?** A small piece of the lesion is removed under local anesthesia (biopsy) and submitted to a pathologist for microscopic examination.

**What are the possible outcomes of the biopsy?** There are three possible outcomes: benign (most frequently), premalignant, or cancer. The pathology report will use pathologic diagnoses such as epithelial hyperplasia/hyperkeratosis or other benign diagnoses, epithelial dysplasia (for premalignant lesions), or squamous cell carcinoma (the most common type of cancer seen in the oral cavity). In epithelial dysplasia, the cells making up the layers of the epithelium look abnormal (atypia), and depending on the amount of abnormal cells seen microscopically, dysplasia may be graded as mild, moderate, severe, or carcinoma in situ (where the atypical cells are in all layers of the epithelium). In squamous cell carcinoma these abnormal cells are no longer confined just to the epithelium but have invaded below the epithelium into deeper tissues.



## PATIENT INFORMATION SHEET

# Premalignant Oral Lesions

**How are patients with oral epithelial dysplasia managed?** Patients with high-grade dysplasia (severe or carcinoma-in-situ) generally have a higher chance for malignant transformation than those with lower-grade dysplasias. It is extremely important that patients with oral epithelial dysplasia be followed by a specialist who is trained to manage these types of lesions. Eliminating high-risk behaviors and promoting protective behaviors (such as a healthy diet) are essential. Surgical removal of a premalignant lesion may or may not be warranted. Regardless of removal, periodic close follow-up of the patient for any visual changes to the lesion site is critical because lesions can recur and transformation into a malignant lesion is possible at anytime.

### QUESTIONS AND ANSWERS ABOUT PREMALIGNANT ORAL LESION:

**Q: My dentist said I have a dysplasia, what does it mean?**

**A:** Dysplasia is a microscopic diagnosis made after looking at a piece of the oral tissue (biopsy) under a microscope. It means that there are premalignant changes that may progress to malignancy but there is no cancer. Not all dysplastic lesions undergo malignant transformation (i.e. turn into a cancer) but since we cannot predict which lesions will, they should all be treated and/or observed closely. You should talk to your dentist and discuss any lifestyle changes you can make to reduce the risk of transformation.

**Q: I have a premalignant lesion on the tongue will this spread to other parts of my mouth or body?**

**A:** Oral premalignant lesions do not typically spread as would a cancer or an infection. However, these lesions can transform into a cancer over time.

**Q: If I quit smoking, will the lesions disappear?**

**A:** Many lesions do improve and in some cases may even disappear. It is certainly desirable to stop smoking for many health reasons. Even after you stop smoking, you are still at risk for oral premalignant lesions, although your risk will decrease over time.

**Q: Are biopsies complicated or painful?**

**A:** No. Biopsies are usually minor procedures taking only a few minutes. Local anesthesia is administered first, a small piece of tissue is taken, some pressure is applied to stop any minor bleeding, and the area may feel a little sore and usually heals without complications.

**Q: If the lesion was removed, do I still need to see my dentist?**

**A:** Yes. Sometimes lesions recur. Sometimes new lesions develop at other sites in the oral cavity. Repeated examinations are essential.

**Q: My dentist has a new device for detecting lesions. Is this really necessary or better than a regular exam?**



## PATIENT INFORMATION SHEET

# Premalignant Oral Lesions

**A:** More studies are needed to assess the benefit of using these new adjunctive devices and they should never replace a routine visual and tactile examination. A possible advantage of these devices is that your dentist may feel they help him/her to better identify abnormalities that might be overlooked during the routine examination.

**Q: Does dysplasia mean I am going eventually to develop cancer?**

**A:** Not necessarily. It means that the tissue doesn't look normal under the microscope, but it is not malignant. It may stay at a dysplastic stage indefinitely without transforming into cancer. It may even go back to being completely normal. Since it is almost impossible to predict which lesions will transform to cancer, all lesions should be followed by your dentist or a specialist. Avoiding high-risk behaviors such as use of tobacco/alcoholic beverages is essential.

**NOTE:** Lesions on the lips that result from sun exposure (*solar cheilitis*) are also premalignant lesions (see **PATIENT INFORMATION SHEET: Lip Changes - Solar Cheilitis**).

### Recommended Links:

The Oral Cancer Foundation

<http://www.oralcancerfoundation.org>

Caring4Cancer

<http://www.caring4cancer.com/go/headneck>

***The information contained in this monograph is for educational purposes only. This information is not a substitute for professional medical advice, diagnosis, or treatment. If you have or suspect you may have a health concern, consult your professional health care provider. Reliance on any information provided in this monograph is solely at your own risk.***

ABOUT THE AMERICAN ACADEMY OF ORAL MEDICINE (AAOM) - The AAOM is a 501c6, nonprofit organization founded in 1945 as the American Academy of Dental Medicine and took its current name in 1966. The members of the American Academy of Oral Medicine include an internationally recognized group of health care professionals and experts concerned with the oral health care of patients who have complex medical conditions, oral mucosal disorders, and / or chronic orofacial pain. Oral Medicine is the field of dentistry concerned with the oral health care of medically complex patients and with the diagnosis and non-surgical management of medically-related disorders or conditions affecting the oral and maxillofacial region.

***The American Academy of Oral Medicine • (425) 778-6162 • [www.aaom.com](http://www.aaom.com) • PO Box 2016 • Edmonds • WA • 98020-9516***